




The image quality of deep-learning image reconstruction of chest CT images on a mediastinal window setting



Diagnostic and Interventional Radiology, Graduate School of Medicine

Assistant Professor Akinori Hata

<https://researchmap.jp/hataakinori>

Abstract

We assessed the image quality of newly developed deep-learning image reconstruction (DLIR) of CT on a mediastinal window setting in comparison to an adaptive statistical iterative reconstruction (ASiR-V). DLIR improved the objective and subjective image quality by reducing noise and streak artifacts and providing finer image texture compared with ASiR, although DLIR showed worse results in the assessment of small vessels.

Background & Results

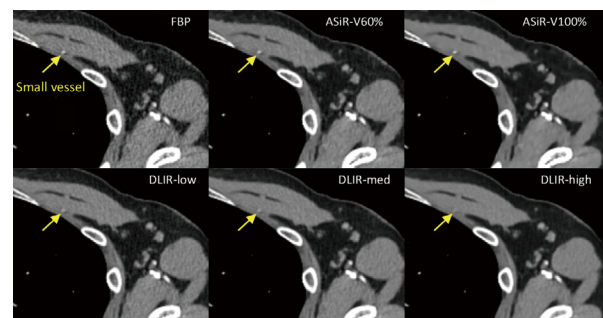
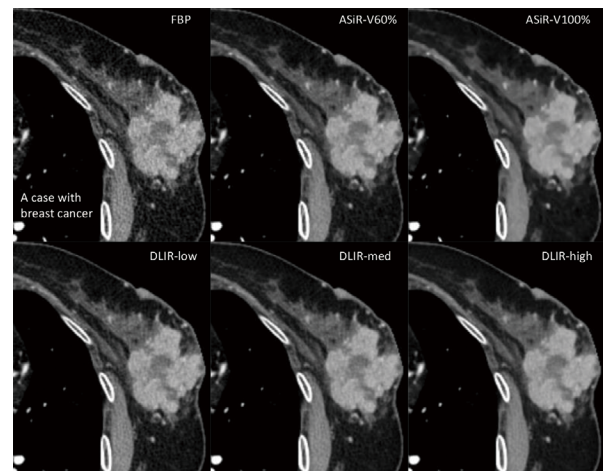
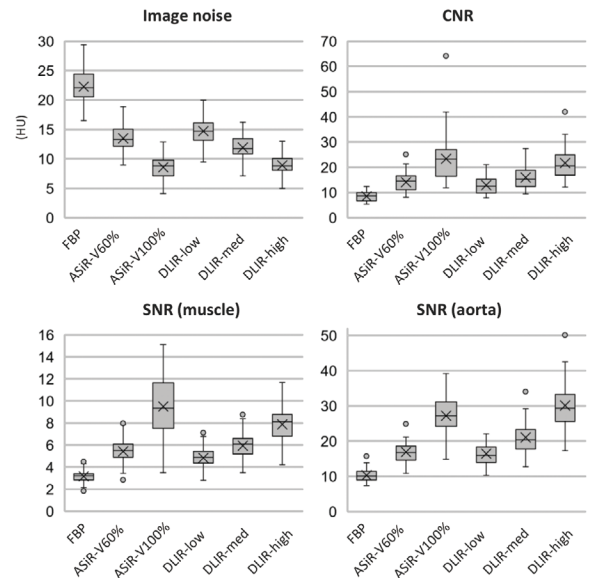
The reconstruction techniques for computed tomography (CT) have been improved, especially by iterative reconstruction (IR). However, IRs have been reported to result in changes in the image texture, and strong level IR is not preferred in the clinical setting. Artificial intelligence, such as deep-learning technologies, is now being applied across various areas and is suitable for CT image reconstruction. Recently, CT vendors have developed DLIR using a large amount of CT data, high-performance graphics processing units, and a long training time. The developed DLIR can be used in the clinical setting with practical reconstruction time.

We evaluated 36 patients who underwent chest CT. The CT images were reconstructed using FBP, ASiR (with 60% and 100% settings), and DLIR (with low, medium, and high settings). Objective image quality including noise, signal-to-noise ratio [SNR], and contrast-to-noise ratio [CNR] were evaluated for all image sets. Subjective image quality compared with FBP images was assessed using a five-point scale in terms of noise, streak artifact, lymph nodes, small vessels, and overall image quality on a mediastinal window setting (width 400 HU, level 60 HU). In addition, the image texture of ASiR-Vs (60% and 100%) and DLIR-high was analyzed subjectively.

We found that DLIR-med and DLIR-high showed significantly less noise, higher SNR, and higher CNR than ASiR-V 60% ($p < 0.0001$). At a higher DLIR setting, the noise was lower and SNR and CNR were higher ($p < 0.0001$). DLIR-high showed the best subjective scores for noise, streak artifact, and overall image quality ($p < 0.0001$). Compared with ASiR-V 60%, DLIR-med and DLIR-high scored worse in the assessment of small vessels ($p < 0.0001$). The image texture of DLIR-high was significantly finer than that of ASiR-V ($p < 0.0001$).

Significance of the research and Future perspective

Our results showed that newly developed DLIR may contribute to the clinical setting by its ability to improve the image quality in mediastinal imaging. It is necessary to evaluate its diagnostic ability for mediastinal diseases, such as esophageal cancer and thymic tumor. In addition, application to CT analysis of extracellular volume and radiomics also needs to be verified. Furthermore, image quality degradation is a major problem on low-dose CT, and verification of dose reduction using DLIR is also considered.



Patent
Treatise
U R L
Keyword

Hata, Akinori; Yanagawa, Masahiro; Yshida Yuriko et al. The image quality of deep-learning image reconstruction of chest CT images on a mediastinal window setting. Clin Radiol. 2021, 76(2), 155.e15-155.e23, doi: 10.1016/j.crad.2020.10.011

CT, image reconstruction, deep learning